

## **Whiplash Syndrome**

### **Kinematic Factors Influencing Pain Patterns**

Joseph F. Cusick, MD; Frank A. Pintar, PhD; Narayan Yoganandan, PhD

From the Department of Neurosurgery, Medical College of Wisconsin

SPINE 2001;26:1252-1258 (June 1, 2001)

#### **FROM ABSTRACT:**

##### **Study Design.**

The overall, local, and segmental kinematic responses of intact human cadaver head-neck complexes undergoing an inertia-type rear-end impact were quantified.

High-speed, high-resolution digital video data of individual facet joint motions during the event were statistically evaluated.

##### **Objectives.**

To deduce the potential for various vertebral column components to be exposed to adverse strains that could result in their participation as pain generators, and to evaluate the abnormal motions that occur during this traumatic event.

##### **Summary of Background Data.**

The vertebral column is known to incur a nonphysiologic curvature during the application of an inertial-type rear-end impact.

No previous studies, however, have quantified the local component motions (facet joint compression and sliding) that occur as a result of rear-impact loading.

##### **Methods.**

Intact human cadaver head-neck complexes underwent inertia-type rear-end impact with predominant moments in the sagittal plane.

High-resolution digital video was used to track the motions of individual facet joints during the event.

Localized angular motion changes at each vertebral segment were analyzed to quantify the abnormal curvature changes.

Facet joint motions were analyzed statistically to obtain differences between anterior and posterior strains.

### Results.

The spine initially assumed an S-curve, with the upper spinal levels in flexion and the lower spinal levels in extension.

The upper C-spine flexion occurred early in the event (approximately 60 ms) during the time the head maintained its static inertia.

The lower cervical spine facet joints demonstrated statistically greater compressive motions in the dorsal aspect than in the ventral aspect, whereas the sliding anteroposterior motions were the same.

### Conclusions.

The nonphysiologic kinematic responses during a whiplash impact may induce stresses in certain upper cervical neural structures or lower facet joints, resulting in possible compromise sufficient to elicit either neuropathic or nociceptive pain.

These dynamic alterations of the upper level (occiput to C2) could impart potentially adverse forces to related neural structures, with subsequent development of a neuropathic pain process.

The pinching of the lower facet joints may lead to potential for local tissue injury and nociceptive pain.

### THESE AUTHORS ALSO NOTE:

There is controversy concerning the pathophysiology of the pain syndromes reported following the acceleration injury to the cervical spine after a vehicle is struck from behind.

General agreement exists that such inertial forces cause strains of various musculoligamentous components in the cervical spine with production of acute cervical pain and headache.

"The persistence of these reports of pain beyond a 6-month interval, however, constitutes a chronic state that does not share the same level of recognition as the acute or subacute entities."

Symptoms of chronic whiplash include:

- (1) Cervical pain
- (2) Headache
- (3) Cognitive difficulties
- (4) Visual obscuration
- (5) Dizziness

The main symptoms are cervical pain and headache.

"These pain entities usually are not associated with objective abnormalities in radiography or clinical examinations, and the causal mechanisms for these symptoms are principals in defining both the existence and basis for this syndrome."

NOCICEPTION PAIN "is the term applied to the reception of signals into the central nervous system evoked by activation of specialized sensory receptors that provide information about potential tissue damage."

"Pain is the conscious perception of nociception."

NEUROPATHIC PAIN includes disturbances in somatosensory processing, other than NOCICEPTION from tissue damage that results in pain.

PSYCHOLOGICAL PAIN may exist when there are neither nociceptive nor neuropathic processes.

"Care must be exercised in concluding that inability to discern tissue damage sufficient to explain the pain should not be taken as proof of a psychological causation."

A fully defined mechanism of injury in the chronic whiplash syndrome has not been clearly established.

Clinical and laboratory studies designed to clarify the pathophysiology of whiplash forces to the cervical spine soft tissues and neural structures "may serve as the basis for production of nociceptive or neuropathic pain processes."

Experimental studies using human cadaver material allow carefully controlled and observed evaluations of kinematic responses from the cervical spine exposed to forces replicating the whiplash experience.

The subsequent deformations of soft tissue and related neural structures by motions exceeding the physiologic range can result in injury.

Experimental studies evaluating kinematic responses of the whole human cadaver spine during simulated whiplash trauma have shown "consistent motion patterns that could adversely affect pain-sensitive structures" in the cervical spine.

This article shows "segmental kinematic responses and explores the implications of possible compromise to specific vertebral column components or

neural elements that may be contributors to the development of both acute and chronic pain syndromes.”

## METHODS

These authors used four intact human cadaver head–neck complexes.

Retroreflective targets were inserted at the anterior vertebral body at every cervical segment, at the mastoid process of the skull, and at the facets, to obtain dynamic kinematic information.

Each specimen was tested with an impact associated with sled acceleration of approximately 4 g, and photographed using a high-speed video camera operating at 4500 frames per second.

Data from the retroreflective markers were calculated to determine the biomechanical kinematics of the head–neck complex.

## RESULTS

Each specimen sustained the inertia-type rear-end impact resulting in consistent pattern of overall kinematics.

- (1) “The lower cervical spine initially was thrust forward (anteriorly), and the head maintained its static inertia.”
- (2) “The spine assumed an S-curve, with the lower spine in local extension and the upper spine in local flexion (approximately 60 ms).”
- (3) “As the head inertially ‘caught up’ with the translating lower spine, it began rearward rotation until eventually the whole spine was in extension (approximately 100 ms).”
- (4) Significant compression at the posterior facet region was noted.

## DISCUSSION

“Because the current study was conducted using human cadaver head–neck complexes, the effects of active musculature were not taken into account.”

Because muscle activity can modulate the biomechanical response, the author’s analysis was limited to approximately 100 ms, which is the time during which the whiplash acceleration pulse is active.

Previous studies indicate that the muscle response time in whiplash to be 125 - 215 ms.

Human volunteer rear impact studies indicate the muscle response time to be 150 - 200 ms for force development.

Therefore, by confining the interpretation of data to the early phase of whiplash response where "muscle activation does not appear to come into play, provides important and relevant information about the initial structural responses in whiplash injury."

"Numerous structures in the cervical region have the potential to serve as pain generators."

This study demonstrated two distinct spinal regions that subject to displacements that may exceed levels of pain-sensitive tissue tolerance.

(1) "During the initial stages of whiplash testing, the cervical spine has an S-shaped configuration with occiput to C2 in flexion as the head lags behind the extension occurring in the lower cervical spine."

(2) Later, the entire cervical spine is in extension.

"These alterations suggest that the region of the upper cervical spine and occiput as well as the lower cervical segments are at potential risk of incurring focal tissue injury that could subserve the development of pain."

"The transient motion-induced S-curve that forms during the intermediate stage of whiplash loading is dynamic, with upper cervical flexion and lower cervical extension. This phenomenon does not occur under normal physiologic movements."

The cervical spine undergoes an S-shape configuration caused by a single, acutely applied dynamic acceleration, and if this motion is excessive, it may cause pain.

"At the craniovertebral junction, during the flexion phase of the initial whiplash process, a variety of pain-sensitive structures could be at risk for compromise."

The suboccipital muscles are susceptible to contractile injury.

While the upper cervical segments are undergoing flexion, the lower cervical spine is in simultaneous extension.

“The related neural elements are part of a continuous tissue tract anchored proximally at the mesencephalon and distally at the exiting nerve roots.”

The “neural structures at the craniovertebral junction are maintained initially in progressive elongation with increased axial tension during the flexion phase.”

This “transient decoupling of the head and neck could increase tension in the upper cervical roots, among which C2 has functional predominance.”

- (1) The C1 nerve root often is absent or rudimentary.
- (2) The C2 dorsal root ganglia (DRGs) is quite large.
- (3) The C2 DRG is medial to the C1–C2 facet and covered by the inferior medial arch of C1.
- (4) The C2 DRG is partially obscured by the posterior atlantoaxial ligament.
- (5) The dorsal ramus of C2 branches into the greater occipital nerve.
- (6) The greater occipital nerve ascends along muscle layers to pass through an aponeurotic attachment at the superior nuchal line.

“The dorsal nerve roots, DRG, spinal nerve, and greater occipital nerve could incur increased tensile forces during the flexion phase as well as possible impingement of the DRG by the posterior atlantoaxial ligament.”

“Injury to these neural structures is followed by a cascade of neuronal events that can cause a change in function or neuronal plasticity, forming the substrate for a neuropathic pain process originating in the suboccipital or occipital regions.” **[WOW!]**

Occipital neuralgia is a diagnostic entity that has well-described clinical features with neuropathic pain aspects, including:

- (1) Lancinating pain in the territory of the greater occipital nerve.
- (2) The pain attacks are often triggered by neck movement, usually are unilateral, with some element of underlying aching occipital pain.
- (3) The convergence from trigeminal and upper cervical dermatomes “may explain the occurrence of associated temporal or retro-orbital pain.”

Research has “demonstrated that DRG injury could cause morphologic changes in the dorsal horn, forming a basis for central sensitization with such structural alterations.”

The potential for C2 DRG injury has been proposed as a basis for neural injury during the latter phases of extension, between the arches of C1 and C2 during.

Patients may present with attributes of occipital neuralgia [NEUROPATHIC] and occipital [NOCICEPTIVE] pain syndromes, making diagnostic differentiation difficult.

“The facet joints of the middle and lower cervical segments constitute another vertebral component undergoing mechanical distortion during the whiplash process.”

“The segmental compression of the posterior aspect of these facet joints (pinching action) has the potential for local tissue injury, which could serve as the basis for nociceptive pain.”

“Facet joint capsules are rich in nociceptors that could undergo excitation by motions that exceed physiologic limits.”

Research has found that whiplash forces could cause stretch in capsular ligaments as well as abnormal joint compression.

This microtrauma at the facet joints is a potential contributor to the pain process.

Facet joint intra-articular meniscoids (synovial folds) inclusions “would be the most likely structures to undergo impingement during facet compression.”

“Inflammation or tearing of the well-developed meniscoids could be part of the acute and chronic tissue changes in the facet joint, resulting in nociceptive pain.”

Acute peripheral sensitization of nociceptors can cause a lowering of thresholds, with excitation occurring at lower stimulus levels, resulting in increased discharge rates and hyperexcitability of dorsal root nociceptive neurons.  
[ALTERED THRESHOLDS]

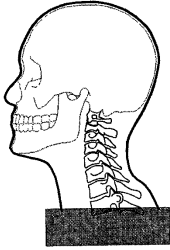
## CONCLUSIONS:

The pain processes in the chronic whiplash syndrome are based in:

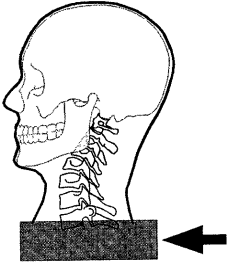
- (1) Alterations of neural elements such as the dorsal roots, DRG, spinal nerves, or peripheral nerves, causing neuropathic pain processes.
- (2) Local tissue injury with nociceptor excitation.
- (3) "The motion changes encountered during the initial phase of the whiplash force may allow adverse distractive forces to act at upper cervical levels, with special attention to the C2 DRG."
- (4) "The lower cervical segments then would be exposed to compressive forces acting on the facet joints, with distortion of the facet joints and capsules."
- (5) These forces may exceed physiologic limits and result in tissue damage, indicating excitation of nociceptors, lowering of response thresholds, and increased firing rates.
- (6) "The latter changes then could increase the potential for a chronic pain process as the peripheral changes induce more central alterations."

## KEY POINTS:

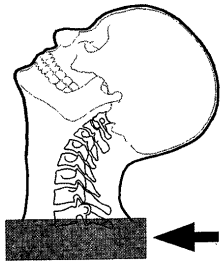
- (1) The intact human cadaver head-neck complex is a suitable experimental model for the study of whiplash kinematics.
- (2) This study verifies the production of a nonphysiologic S-curve configuration in the C-spine, which results from the whiplash force applied to the intact human cadaver head-neck complex.
- (3) Flexion at the upper segment may induce increased tensile forces that affect related neural structures, serving as the origin of a neuropathic pain process.
- (4) Compression motion at the lower-segment facet joints demonstrates a focal component of increased compression in the posterior aspect of the facet joint (pinching), suggesting a risk of local injury, which is the basis of a nociceptive pain process.



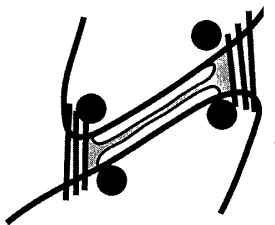
Initial Neutral Position Prior To Impact



Initial Forward translation of the base of the spine causing an S-curve. The head maintains its static inertia. Occurs at about 60 ms

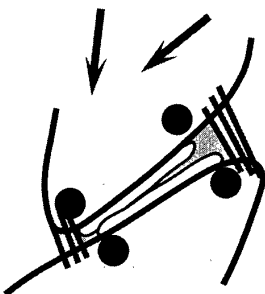


General extension occurring at about 100 ms



ANTERIOR

Neutral Normal Facet Prior To Whiplash



ANTERIOR

Lower Cervical Spine Facet Joint Pinching

Anterior Facet Capsule Tearing

Posterior Translation Sliding Of The Superior Facet Damaging Cartilage